



Dear Friends and Colleagues,

Greetings from the “Fertility Preservation Society” of India.

In this issue, we present a recent publication that discusses **Fertility preservation in ovarian tumours**. Ovarian tumours are first diagnosed by gynaecologists giving them a unique opportunity to discuss fertility preservation. **Fertility sparing surgery** is advocated in early stages and **FP** is advised when **FSS** is not possible or patient needs to delay pregnancy. The most effective **chemotherapeutic regimen** for epithelial OC is a combination of a platinum compound and a taxane which have an intermediate risk on fertility.

I hope you find this helpful in treating your patients.

Happy reading !

Nalini Mahajan

Founder President FPSI

Oncofertility e-Update: July 2019

Fertility Preservation Society (India)

Fertility preservation in ovarian tumours

Tomao F, DI Pinto A, Sassu CM et al. Ecancermedalscience 2018

Compiled by

Dr. Jasneet Kaur (Consultant: Milann Fertility Centre, Chandigarh)

Introduction: 3%–14% of ovarian cancers (OC) are diagnosed during reproductive years. *When diagnosed at stage 1A–B the overall 5 year survival rate in women ≤ 44 years is 91.2%.* The challenge in these women is to remove and eliminate cancer cells from an organ which is vital to fertility. **Fertility sparing surgery (FSS)** is advocated in early cases till a women has completed her family and fertility preservation (FP) techniques are offered when FSS is not possible. **FP techniques include oocyte and embryo cryopreservation and Invitro maturation (IVM). Ovarian tissue cryopreservation (OTC) is not recommended in these women.** The most effective chemotherapeutic regimen for epithelial OC is a combination of a platinum compound and a taxane. The impact on fertility of taxanes and platinum based chemotherapeutic agents is an intermediate risk level of amenorrhoea (30%–70%), whereas

protocols containing antimetabolites and anthracyclines are related to a lower risk (less than 30%).

Fertility Sparing Surgeries: Involves preservation of ovarian tissue in one or both adnexa and/or the uterus in patients with OC in need of FP (Fig 1).

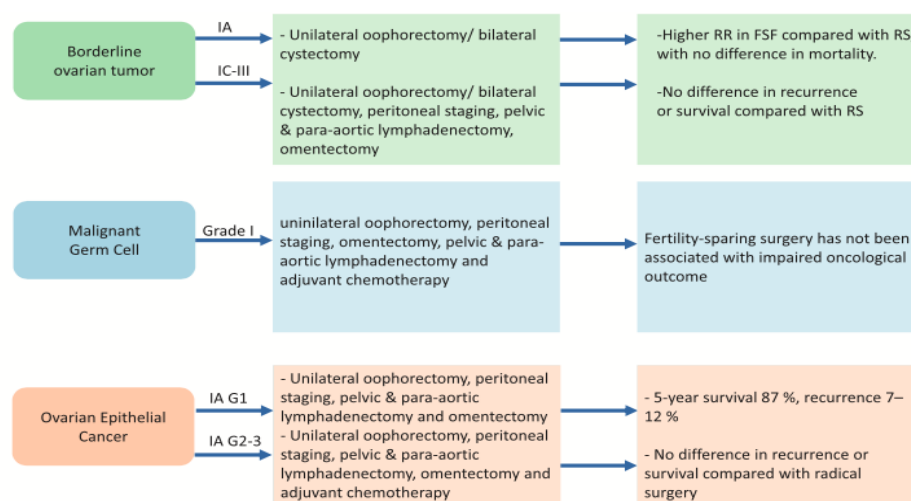


Figure 1. Fertility sparing strategies in OC patients. RR = recurrence rate, FSF = fertility sparing surgery, RS = radical surgery.

Borderline ovarian tumours (BOTs): Comprise 10%–20% of ovarian epithelial tumours and are typically diagnosed during reproductive years. Survival rates are about 99%, with a 70-month disease free survival (DFS) in cases of stage I tumours, and 89% in stage III tumours. Cystectomy or unilateral salpingo oophorectomy (USO) have been performed in patients desiring fertility. FSS's are associated with a higher risk of relapse but not with increased mortality. The risk of relapse is higher for women <30 years, bilateral tumours, presence of micropapillae on histology, stage and presence of invasive implants and the type of surgery performed (cystectomy versus adnexectomy)

Women desirous of an offspring are advised timed intercourse 3 months post surgery

Women without a partner or those wanting to postpone pregnancy can be advised oocyte cryopreservation.

Literature suggests that it is unclear whether ART is associated with an increased risk of recurrence, but it is underlined that most recurrences were BOT and were successfully managed by surgery.

Germ cell tumours: Malignant ovarian germ cell tumours (MOGCTs) are rare cancers (3%–5% of ovarian tumours) but 83% of cases affect women under the age of 40 years. Fertility preservation is therefore an important aspect in the management of these neoplasms. Due to the rapid growth and early symptoms tumor is diagnosed in early stages. USO with peritoneal staging and retroperitoneal staging if indicated, is the treatment of choice in early stage MOGCT. There is no survival difference after unilateral or bilateral salpingo-oophorectomy (BSO) when MOGCT are confined to one ovary. Bilateral disease is uncommon and biopsy of contralateral normal ovary is not advised owing to risk of adhesions and impairment of ovarian reserve.

• **Pure dysgerminoma:** Several authors suggest FSS for all stages with a 10 year disease free survival (DFS) >90% and overall survival (OS) 100%.

- **Yolk sac tumours (non-dysgerminomatous tumours):** Early stage, FSS is feasible. For higher stages, standard dose bleomycin, etoposide and cisplatin (BEP) chemotherapy (CT) following FSS has been associated with favorable OS rates and no apparent compromise of fertility rates. Serum AFP is a reliable marker for diagnosis and clinical decision making after surgery or advanced disease management.

- **Immature ovarian teratoma (non-dysgerminomatous tumours)** For stage 1 grade 2–3, adjuvant chemotherapy following FSS has been recommended by some while an expectant approach with BEP administration only in case of relapse has been advocated by others

Reproductive function : more than 80% of patients retain reproductive function after CT and surgery.

Oocyte cryopreservation could be proposed to all adolescent patients and to all those who have not yet planned a pregnancy. COH could also be considered after 12 months from CT.

Malignant sex cord stromal tumours: Include granulosa cell tumours (most common) and Sertoli Leydig cell tumours. Rare and associated with good prognosis. Most patients with granulosa tumours present with early-stage disease. The disease is typically indolent. Patients with stage IA or IC sex cord stromal tumours desiring to preserve their fertility should be treated with FSS. Although complete staging is recommended for all patients, lymphadenectomy may be omitted for stage IA or IC. Completion surgery should be considered after childbearing is finished. For patients with high-risk stage I tumours (tumour rupture, stage 1C, poorly differentiated tumour and tumour size >10–15 cm), *observation or consideration of platinum-based chemotherapy is indicated*. Patients with surgical findings of low-risk stage I tumor (i.e. without high-risk features) should be observed.

Epithelial tumours: The standard treatment for FIGO stage I–II EOC is TAH+BSO, peritoneal sampling, omentectomy, both pelvic and para-aortic lymphadenectomy. According to the available guidelines, *in women wishing to maintain fertility, conservative surgery can be performed, for all grades at stage IA or IC*. FSS is debated for high-risk patients (clear cell, stage > or equal IAG3). ESMO and ESGO guidelines advocate a *conservative approach limited to G1-2 IA and IC EOC with unilateral involvement in mucinous, serous, endometrioid or mixed histotype*. In the case of endometrial histotype, an endometrial biopsy is suggested, while in the case of mucinous histotype, appendectomy is recommended to exclude intestinal origin of tumor. Laparoscopic approach is feasible but tumours > 10 cm are correlated with a higher risk of rupture and spillage during laparoscopy (88% versus 9% laparotomy).

Carcinosarcomas: Malignant Mixed Müllerian Tumours (MMMTs) are rare tumours with a poor prognosis. MMMTs are not candidates for FSS regardless of age.

Patients with BRCA mutation. BRCA mutations, especially BRCA1, has been associated with decreased ovarian reserve, primary ovarian insufficiency, decreased fecundity and early menopause. Assessment of OR helps in counseling young adults for FP. Oocyte CP is feasible before 40 years. OTC is not recommended. Current recommendation is that mutation carriers should complete childbearing and then undergo BSO around 35–40 years for BRCA1 mutation & 45–50 years for BRCA2 mutations.

Actual and future perspectives for hysterectomised women (beyond uterus transplantation): Women who have undergone hysterectomy will need to consider surrogacy. Recently, successful uterine transplantation was reported but application of this technique in clinical

practice is still limited due to the risk of cancer recurrence in immunocompromised patients and the possible vascular abnormalities after pelvic radiation.

Use of Fertoprotective agents: GnRH agonist and antagonist is promoted.

Fertility preservation techniques: In case of the necessity of radical surgery

Oocyte/Embryo cryopreservation: They are established techniques. Valid option for patients with unilateral OC. Oocytes can be retrieved from the unaffected ovary during surgery, with COH. However it can delay cancer treatment and [may stimulate the rapid proliferation of hormone dependent cancer cells such as those in granulosa cell tumor.](#)

Ovarian tissue cryopreservation: OTC is not an option for women with OC or at high risk of developing OC (BRCA1-2 carrier patients). However, there are controversial reports suggesting it to be an option in young women at very low risk of OC. [A primary concern regarding auto transplantation of cryopreserved ovarian tissue in ovarian cancer survivors is risk of reimplantation and dissemination of the primary cancer.](#)

Isolation of individual ovarian follicles from ovarian tissues and subsequent in vitro culture (IVM) may minimize the risk of transmission and reimplantation of malignant cells.